

See discussions, stats, and author profiles for this publication at: <https://www.researchgate.net/publication/313300048>

# Tubercular Tenosynovitis of Hand: A Rare Presentation

Article in *Journal of Orthopaedic Case Reports* · October 2016

DOI: 10.13107/jocr.2250-0685.576

CITATIONS

18

READS

55

4 authors, including:



**Ashish Devgan**

PGIMS, Rohtak

41 PUBLICATIONS 429 CITATIONS

[SEE PROFILE](#)



**Jitendra Wadhvani**

Pt. BD Sharma University of Health Sciences, Rohtak

28 PUBLICATIONS 164 CITATIONS

[SEE PROFILE](#)

Some of the authors of this publication are also working on these related projects:



Ankle fracture fixation technique [View project](#)



SPORTS INJURIES [View project](#)

# Tubercular Tenosynovitis of Hand: A Rare Presentation

Aditya Jain<sup>1</sup>, Rajesh Rohilla<sup>1</sup>, Ashish Devgan<sup>1</sup>, Jitendra Wadhvani<sup>1</sup>

## What to Learn from this Article?

TB tenosynovitis is a condition which can easily be misdiagnosed and should undergo all the blood, radiological and histopathological investigations to arrive at accurate diagnosis.

## Abstract

**Introduction:** Tuberculosis tenosynovitis of the wrist and hand is an unusual condition. It mimics a number of other clinical conditions such as ganglion, De quervan's disease, carpal tunnel syndrome, granulomatous gout, neurofibroma, and haemangioma.

**Case Report:** We present case of 58-year-old male patient with swelling over thenar region of left hand where the initial fine needle aspiration cytology (FNAC) report suggested diagnosis of ganglion/synovial cyst, but the patient did not improve with conservative treatment. FNAC was repeated which showed granulomatous inflammation consistent with the clinical diagnosis of tuberculosis and antitubercular therapy for 9 months was given. Swelling disappeared and normal range of movements was attained in adjacent joints at final follow-up of 12 months from initiation of antitubercular treatment (ATT).

**Conclusion:** The literature on the management of tubercular tenosynovitis has mostly incorporated surgical method as one of the first-line treatments. We report an unusual case, where the tenosynovitis of wrist completely responded within 12 months of ATT without any need of surgical treatment.

**Keywords:** Tuberculosis, Tenosynovitis, Ganglion, ATT.

## Introduction

Tuberculosis (TB) can affect any organs/systems of the human body and have variable presentation in each system. The musculoskeletal system is involved in approximately 10% of all extrapulmonary involvements [1]. TB tenosynovitis of the wrist and hand is an unusual condition [2, 3]. The major dilemma in diagnosing these uncommon presentations is the presence of the non-specific clinical signs which can be misleading as they mimic a number of other clinical conditions such as ganglion, De quervain's disease, carpal tunnel syndrome, and granulomatous gout [4, 5, 6].

We report an unusual case of tubercular tenosynovitis of the left hand in a 58-year-old male who had been treated as ganglion. The purpose of this report is to highlight the importance of radiological and histopathological investigations in these "suspicious" cases. Further, there is only handful of literature available which highlights the management of tubercular tenosynovitis with anti-tubercular therapy only without operative treatment.

## Case Report

We present a case of 58-year-old male patient who presented to the outpatient department of the author's tertiary level institute with swelling

### Access this article online

Website:  
www.jocr.co.in

DOI:  
2250-0685.576

### Author's Photo Gallery



Dr. Aditya Jain



Dr. Rajesh Rohilla



Dr. Ashish Devgan



Dr. Jitendra Wadhvani

<sup>1</sup>Department of Orthopaedics, Pt. B.D. Sharma PGIMS, Rohtak, Haryana, India.

### Address of Correspondence

Dr. Aditya Jain,  
Room No.200, Doctors Hostel, Pt. B. D. Sharma PGIMS, Rohtak, Haryana, India.  
E-mail: adityajain0730@gmail.com

Copyright © 2016 by Journal of Orthopaedic Case Reports

Journal of Orthopaedic Case Reports | pISSN 2250-0685 | eISSN 2321-3817 | Available on www.jocr.co.in | doi:10.13107/jocr.2250-0685.576

This is an Open Access article distributed under the terms of the Creative Commons Attribution Non-Commercial License (<http://creativecommons.org/licenses/by-nc/3.0>) which permits unrestricted non-commercial use, distribution, and reproduction in any medium, provided the original work is properly cited.

over thenar region of the left hand. He was a fully independent, nonsmoker, right handed, asthmatic patient on inhalational corticosteroids since 5 years. He noted a small, painful swelling in left thenar region 5 months back. He visited a local orthopedician who advised him to get fine needle aspiration cytology (FNAC) of the swelling. FNAC report suggested the diagnosis of ganglion/synovial cyst and conservative treatment was started, but the swelling did not decrease in size, rather gradually increased in size and became painful with other signs of inflammation. It also affected the movements at the wrist.

When the patient presented to the author's institute, there was a single, soft, fluctuant swelling of 5 cm × 4 cm over left thenar region with ill-defined margins, erythematic overlying skin. Swelling was not adherent to underlying structures and was nonpulsatile (Fig. 1). There was diffuse edema over the volar surface of the left wrist and distal forearm associated with erythema and tenderness. Neurovascular examination of the extremity was normal. The systemic examination was unremarkable except for presenting swellings. There was no history of fever, trauma, joint pain, rashes, prolonged cough, decreased appetite, weight loss as well as no known or traceable history of contact with TB.

Chest radiograph of this patient was normal. No evidence of radiographic pulmonary TB was seen. Magnetic resonance imaging (MRI) was subsequently performed to assess extent of lesion. It revealed a large peripherally enhancing cystic lesion containing multiple loose bodies involving thenar eminence of left palm. Tenosynovitis of flexor carpi radialis was also seen, and a small cystic lesion (0.9 cm × 0.5 cm × 0.4 cm) was seen superficial to flexor retinaculum laterally. Underlying carpal bones revealed focal area of altered signal intensity, with no evidence of joint effusion (Fig. 2). FNAC was repeated which showed granulomatous inflammation with caseation, consistent with the clinical diagnosis of TB (Fig. 3) and the sample was sent for culture. The patient was started on antitubercular therapy with four first-line drugs (isoniazid, Rifampicin, Pyrazinamide and Ethambutol) for 4 months followed by biotherapy (Isoniazid, Rifampicin) for 5 months. Further, mycobacterium TB was isolated in the culture. Complete blood count revealed elevated white blood cell count of  $14.8 \times 10^9/L$  with a high neutrophil differential count of 90% but low lymphocyte differential count of 5%. Erythrocyte sedimentation rate was also elevated (50 mm/h).

The patient was compliant to the treatment and did not have any major adverse drug effects. Swelling disappeared and normal range

of movements was attained in adjacent joints at final follow-up of 12 months from initiation of antitubercular treatment (Fig. 1). Supervised physiotherapy for fingers and wrist was initiated especially in the initial treatment phase to prevent adhesions and contractures and improve functional results.

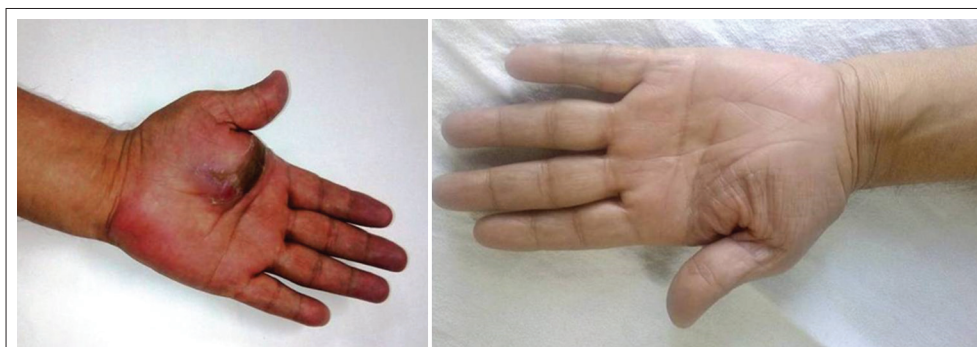
## Discussion

Mycobacterium TB infection is mostly seen in patients with impaired cell-mediated immunity, which may be disseminated readily resulting in high mortality rates. The known predisposing factors include age >60 years, malnutrition, alcohol abuse, low socioeconomic status, history of or exposure to TB, immunosuppression from any cause, and intake of corticosteroids. The two theories regarding the pathogenesis of TB tenosynovitis direct inoculation and hematogenous dissemination from a primary focus. Infection appears to start in the synovium and then gradually spread to the tendons and even the bones.

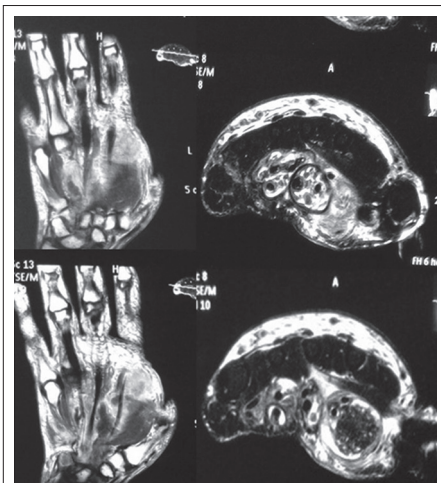TB tenosynovitis selectively targets the wrist and volar aspect of the hand, where it accounts for 5% of cases of osteoarticular TB [7]. The main setback remains the difficulty in diagnosing the disease because of non-specific clinical signs that point to a number of other possibilities such as other mycobacterial infections, pyogenic and fungal infections, brucellosis, foreign body tenosynovitis, sarcoidosis, rheumatoid arthritis (RA), gouty arthritis, De quervain's disease, and ganglion [3, 4, 6]. The case reported here was initially misdiagnosed as ganglion at another hospital.

TB tenosynovitis may appear in different forms as a result of the long duration of the disease, the varying resistance of the individual, and the varying virulence of the organism. Patients with tubercular tenosynovitis usually present with an insidious, slow-growing, sausage-like mass along the inflamed tendon with minimal or no pain; sometimes may present with discharging sinus and carpal tunnel syndrome. This explains the presentation of our case, who initially presented to outpatient department with slow growing, insidious, painless swelling and later (after being treated as ganglion only) developed pain, increased size of swelling, and other signs of inflammation. Our patient also had a history of inhalational corticosteroid intake since 5 years.

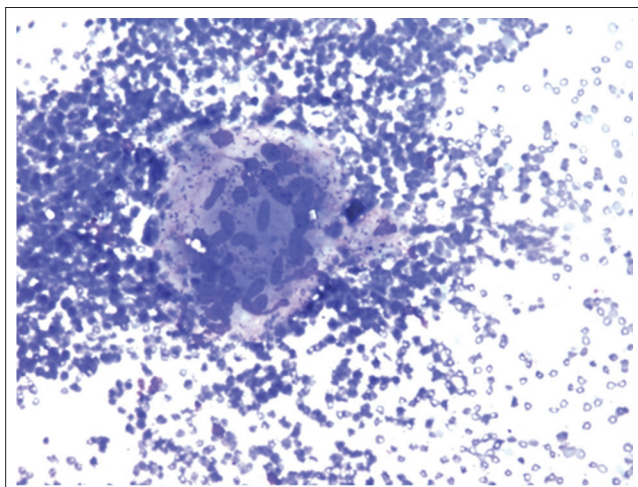
Further, plain radiograph of the left hand showed only a large soft tissue mass on the thenar aspect of the hand with no bony involvement. MRI discovered a large peripherally enhancing cystic lesion containing



**Figure 1:** Clinical photograph showing- (Left) Pretreatment lesion-single, soft, fluctuant swelling over left thenar region with ill-defined margins, erythematic and discolored overlying skin. There is also associated diffuse edema of wrist and distal forearm (left). Post treatment at 12 months follow-up showing healed lesion.



**Figure 2:** Magnetic resonance imaging wrist and hand showing a large peripherally enhancing cystic lesion containing multiple loose bodies involving the flexor tendons of forearm and thenar eminence of left palm.



**Figure 3:** Histopathological image showing granulomatous inflammation consistent with the clinical diagnosis of tuberculosis.

multiple loose bodies with focal area of altered signals in underlying carpal bones (Fig. 2). Finally, repeat FNAC was performed which showed granulomatous inflammation consistent with TB (Fig. 3) and culture confirmed the growth of mycobacterium TB.

MRI may show thickening of the synovial membrane, increased vascularity and fluid within the tendon sheath, reactive inflammation and swelling around the tendon. In contrast to acute suppurative tenosynovitis, where synovial sheath fluid is the predominant feature, relatively little synovial sheath fluid is characteristic of TB pathology [3, 7].

Multiple rice bodies are composed of amorphous material surrounded by collagen and fibrin with unknown etiology. Although this is a rare occurrence related to RA, rice bodies can also be seen in systemic lupus erythematosus, seronegative arthritis, infectious arthritis (TB, atypical mycobacterial infection), and nonspecific arthritis [8].

The literature on the management of tubercular tenosynovitis has mostly incorporated surgical method as one of the first-line treatment. Surgical debridement is controversial [9, 10] Tuli states that surgical debridement should be performed in patients who do not respond to four or five months of chemotherapy [9]. Furthermore, surgery may cause adhesions especially in palmar side of hand so antitubercular therapy should be tried first.

Only a few studies are available which managed the disease with antitubercular therapy (ATT) alone without the primary surgical procedure. We report an unusual case, where the tenosynovitis of wrist completely responded within 12 months of ATT without any need of surgical treatment (Fig. 1).

### Conclusion

TB is still a major health threat in developing countries like India. Although rare, orthopedicians must consider TB tenosynovitis of wrist and hand as a differential, where patient presents even with an innocent mass lesion at the wrist. The patient should undergo a thorough clinical, radiological and histopathological examination, to diagnose the tubercular tenosynovitis. Early diagnosis and instigation of ATT with or without surgical procedure gives good functional results. Close follow-up is necessary to avoid possible complications and recurrence.

### Clinical Message

Tubercular tenosynovitis of hand is a rare presentation which can mimic many other clinical conditions due to which it can be easily misdiagnosed and mistreated. Once diagnosed, it can be treated with antitubercular chemotherapy without the need of surgical treatment.

### References

- Lee SH, Abramson SB. Infections of the musculoskeletal system by *M. tuberculosis*. In: Rom WN, Garay SM, editors. Tuberculosis. 4<sup>th</sup> ed. New York, NY: Little, Brown and Company; 1996. p. 635-644.
- Diwanji SR, Shah ND. Tuberculous tenosynovitis of flexor digitorum longus tendon. Orthopedics 2008;31(5):499.
- Hoffman KL, Bergman AG, Hoffman DK, Harris DP. Tuberculous tenosynovitis of the flexor tendons of the wrist: MR imaging with pathologic correlation. Skeletal Radiol 1996;25(2):186-188.
- Chen WS, Eng HL. Tuberculous tenosynovitis of the wrist mimicking de Quervain's disease. J Rheumatol 1994;21(4):763-765.
- Kostman JR, Rush P, Reginato AJ. Granulomatous tophaceous gout mimicking tuberculous tenosynovitis: Report of two cases. Clin Infect Dis 1995;21(1):217-219.
- Gokkus K, Sagtas E, Aydin AT. Tuberculous tenosynovitis of the wrist mimicking a volar wrist ganglion cyst and carpal tunnel syndrome. Turk J Rheumatol 2013;28:128-131.

7. Fnini S, Ouarab M, Rafai M, Cohen D, Largab A, Trafteh M. An uncommon occupational accident: Tuberculous tenosynovitis of the extensor tendons of the hand. *Chir Main* 1999;18(4):309-312.
8. Ergun T, Lakadamyali H, Aydin O. Multiple rice body formation accompanying the chronic nonspecific tenosynovitis of flexor tendons of the wrist. *Radiat Med* 2008;26(9):545-548.
9. Bush DC, Schneider LH. Tuberculosis of the hand and wrist. *J Hand Surg Am* 1984;9(3):391-398.
10. Tuli SM. General principles of osteoarticular tuberculosis. *Clin Orthop Relat Res* 2002;398:11-19.

Conflict of Interest: Nil  
Source of Support: None

#### How to Cite this Article

Jain A, Rohilla R, Devgan A, Wadhwani J. Tubercular Tenosynovitis of Hand: A Rare Presentation. *Journal of Orthopaedic Case Reports* 2016 Sep-Oct;6(4): 69-72.